

Selective Death of Lens Epithelial Cells Using Demineralized Water and Triton X-100 With PerfectCapsule Sealed Capsule Irrigation

A Histological Study in Rabbit Eyes

Anthony J. Maloof, MBBS, MBiomedE, FRANZCO, FRACS; Suresh K. Pandey, MD; Geoff Neilson, BSc; E. John Milverton, MBBS, DO, FRANZCO, FRCOphth

Background: Sealed irrigation of the capsular bag after removal of the cataractous lens isolates the interior of the capsular bag from the anterior segment, permitting isolated targeting of lens epithelial cells (LECs) in vivo using pharmacologic agents while minimizing the risk of damage to other intraocular structures.

Objectives: To assess the ability to deliver a nonspecific, extremely toxic agent (Triton X-100) directly to the LECs after crystalline lens removal, and to assess the eyes histologically for evidence of collateral damage.

Methods: Twelve eyes from 6 New Zealand White rabbits were divided into 3 groups of 4 eyes that underwent phacoaspiration of the crystalline lens. Group 1 was a control. In group 2, the anterior segment was irrigated with Triton X-100 and demineralized water for injection for 5 minutes. In group 3, the lens capsule was isolated from the anterior segment using sealed capsule irrigation (SCI) with PerfectCapsule (Milvella Pty Ltd, Sydney, Australia). After surgery, the rabbits were humanely euthanized. The enucleated eyes were immediately fixed in 10% neutral buffered formalin, histological analysis was performed to assess the corneal endothelium, iris, and retina, and the capsular bag and residual equatorial LECs were assessed.

Results: The capsular bag was sealed and inflated under SCI in all treated eyes in group 3. Histological evaluation revealed no evidence of collateral damage in group

1 and group 3. Significant histological damage to the cornea, iris, and peripheral retina was noted in group 2. Histological evaluation of each capsular bag suggests presence of LECs in group 1 and group 2. In the presence of SCI, Triton X-100 caused almost complete destruction of LECs in the capsular bag.

Conclusions: Results suggest that SCI allows selective delivery of toxic agents directly into the capsular bag, preventing collateral damage to surrounding intraocular structures. The PerfectCapsule device kept the capsular bag well inflated intraoperatively, which may allow the isolated, safe delivery of pharmacologic agents into the capsular bag during cataract surgery.

Clinical Relevance: Postoperative proliferation of LECs in the capsular bag remains the most frequent complication of cataract surgery. Unprotected intraocular infusion of cytotoxic drugs, antimetabolites, or hypo-osmotic agents during cataract surgery has the potential risk of causing toxic effects in corneal endothelium and adjacent intraocular tissues. Selective delivery of pharmacologic/hypo-osmotic agents into the capsular bag requires positive pressure inflation of the bag and is now possible using an SCI device. This device allows the surgeon to reseal the capsular bag intraoperatively, achieve positive pressure inflation of the capsular bag, and direct selective targeting of LECs.

Arch Ophthalmol. 2005;123:1378-1384

Author Affiliations: Centre for Vision Research, Department of Ophthalmology, University of Sydney, Westmead Hospital, Westmead, Australia (Drs Maloof and Pandey); Intraocular Implant Unit, Sydney Eye Hospital, Sydney, Australia (Drs Maloof, Pandey, and Milverton); John A. Moran Eye Center, Department of Ophthalmology & Visual Sciences, University of Utah, Salt Lake City (Dr Pandey); and Milvella Pty Ltd, Epping, Australia (Mr Neilson).

EXTRACAPSULAR CATARACT EXTRACTION with posterior chamber intraocular lens implantation has become the procedure of choice in almost all uncomplicated cataract procedures worldwide. A major persistent complication of this technique is posterior capsule opacification (PCO); secondary to cataract or after cataract), which occurs in 15% to 50% of eyes followed up for 3 to 5 years postoperatively.¹⁻⁸ In children and young adults, PCO is expected in almost all cases within 1 year after cataract surgery.⁹

In view of the large number of cataract surgeries performed, PCO has important medical, social, and economic implications. Although it is current practice to clear the visual axis with Nd:YAG laser capsulotomy, ocular complications such as retinal detachment and cystoid macular edema may occur. This procedure is expensive, costing US Medicare an estimated \$250 million per annum.³

The prevention of PCO is a big challenge in ophthalmic research owing to medical and financial implications. Advances in the development of technologically new in-

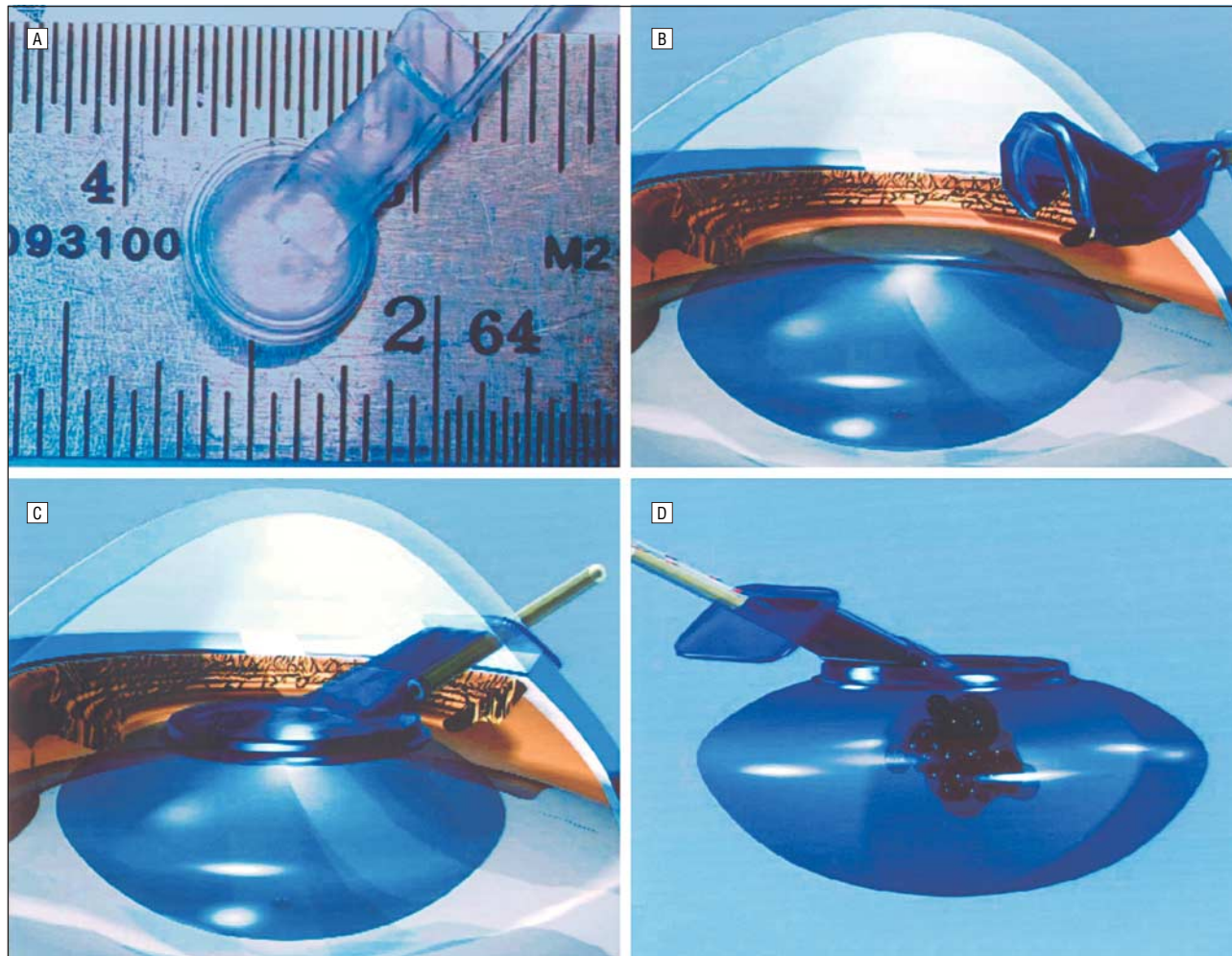


Figure 1. Schematic diagrams illustrating the concept of the sealed capsule irrigating device (PerfectCapsule; Milvella Pty Ltd, Sydney, Australia). This device is designed to hold the capsular bag by means of a toroidal suction ring connected to a locking suction syringe. An irrigation/aspiration port allows fluids to be injected through the device into the empty capsule, significantly reducing the possibility of potentially toxic irrigation fluid coming into contact with other ocular structures. A, Sealed capsule irrigation device viewed from the top. It consists of a round plate that seals against the capsule and an extension arm that passes outside the wound. Ruler is in millimeters. B, Sealed capsule irrigation device is folded and inserted through a 3-mm incision. C, Sealed capsule irrigation device is placed onto the capsular bag and vacuum attached by a syringe. D, Internal irrigation of the capsular bag using the sealed capsule irrigation device.

traocular lenses, particularly in multifocal, accommodative, and refractive implants, are limited by PCO. The square edge profile of a posterior chamber intraocular lens delays PCO on account of the barrier effect¹⁰⁻¹³; however, this is only a temporary measure to delay the PCO.

The pathogenesis of PCO is attributed to the persistence and response of lens epithelial cells (LECs). A fibrotic type of PCO can be followed by capsular bag contraction. This is a consequence of proliferation and fibrous metaplasia of anterior and equatorial LECs.¹³

To target LECs, a number of cytotoxic agents have been investigated previously in human and animal studies, ex vivo capsular bag organ culture, and LEC cultures in vitro.¹⁴⁻²⁶ Although the aim was to selectively target the LECs, the researchers were unable to avoid toxic effects to other intraocular tissues, such as the sensitive corneal endothelium, which was a concern while using these agents. Selective targeting of LECs to prevent PCO can now be safely conducted using sealed capsule irrigation (SCI) by precise delivery of known doses of pharmacologic agents to eliminate the risk of toxic side effects to surrounding intraocular structures.

The SCI device (PerfectCapsule; Milvella Pty Ltd, Sydney, Australia) exteriorizes the internal capsular bag and permits mechanical isolation of the capsular bag from the rest of the eye after removal of the crystalline lens (**Figure 1**).²⁷ The PerfectCapsule inflates the capsular bag and allows for the isolated delivery of pharmacologic agents into the capsular bag during surgery without the attendant risk of direct damage to other ocular tissues from exposure to pharmacologic agents. The SCI device may be used to eliminate or modulate LEC activity after cataract surgery, and it may lead to less postoperative opacification in the capsular bag. Recently, we investigated the efficacy of demineralized water for injection (DWI) for SCI in human eyes as well as the effect of DWI on residual LECs on the anterior lens capsule in an in vitro study.^{27,28} The rationale for these agents is that DWI induces cell lysis by osmotic stress.²⁸ Triton X-100 (TTX-100, 1% vol/vol; Amresco, Solon, Ohio) is an extremely toxic, nonspecific detergent that lyses cell walls, resulting in irreversible cell destruction.²⁹

The present experimental study was designed to assess the ability to deliver TTX-100 (mixed with DWI) directly to the LECs after crystalline lens removal in rabbit eyes using the sealed (with PerfectCapsule) vs nonsealed conventional irrigation of the capsular bag. We have also performed a histological study to evaluate collateral damage (defined as damage to other intraocular structures, such as corneal endothelium, iris, ciliary body, and retina) after continuous irrigation of TTX-100 (mixed with DWI) for a period of 5 minutes with or without SCI.

METHODS

ANIMALS

Six New Zealand albino rabbits weighing between 2.5 kg and 3.5 kg were used. The animals were kept under standardized conditions in separate cages and given tap water and food ad libitum. The experiments in this study adhered to the Association for Research in Vision and Ophthalmology statement for the use of animals in ophthalmic and vision research.

SEALED CAPSULE IRRIGATION DEVICE

The SCI device (PerfectCapsule) is made from biomedical-grade soft silicone and allows the surgeon to reseat the capsular bag. The device consists of a rounded plate containing a suction ring, which abuts the anterior capsule, and an extension arm that passes through a clear corneal wound. This extension arm carries a vacuum channel that supplies vacuum to the suction ring, and a combined irrigation and aspiration channel. The irrigation and outflow channels allow for communication between the sealed capsular bag and the external eye (Figure 1).

CONTROL AND EXPERIMENTAL GROUPS

The rabbits were divided into 3 groups:

Group 1: Two rabbits (4 eyes) underwent surgery using phacoemulsification, without any treatment (control group).

Group 2: Two rabbits (4 eyes) underwent surgery using phacoemulsification, and they were subjected to irrigation of the capsular bag with TTX-100 and DWI for 5 minutes, delivered via a preloaded 20-mL syringe with a 27-gauge cannula inserted into the main wound.

Group 3: Two rabbits (4 eyes) underwent surgery using phacoemulsification, and they underwent selective irrigation of the capsular bag with TTX-100 and DWI for 5 minutes using SCI with PerfectCapsule.

SURGICAL TECHNIQUE

All of the procedures were performed under general anesthesia at the Centre for Vision Research, Department of Ophthalmology, University of Sydney, Westmead Hospital, Westmead, Australia, by the same surgeon (A.J.M.). The same technique was used in all 3 groups, with the exception of the use of sealed capsule irrigation of capsular bags.

Shortly after pupil dilatation, a corneal incision of approximately 2 mm was made close to the limbus with a Superblade (Alcon Laboratories, Inc, Ft Worth, Tex). Viscoelastic solution (1% Provisc; Alcon) was injected into the anterior chamber. The corneal incision was enlarged to 3.2 mm with an angled ophthalmic slit knife. A continuous circular capsulorrhexis of approximately 4.5 mm in diameter was performed using capsulorrhexis forceps. Hydrodissection was performed prior to

phacoaspiration. The soft lens matter was aspirated using phacoemulsification (Prestige phacoemulsifier; Advanced Medical Optics, Santa Ana, Calif). Following crystalline lens removal, cortical cleanup was performed and the capsular bag was carefully washed using the irrigating solution. Approximately 50 mL of irrigating solution was used during the procedure in each eye. This was performed for a period of 5 minutes. However, no attempt was made to remove the LECs from the lens capsule.

In group 1 eyes, capsular bag irrigation was performed with balanced salt solution only (control). Group 2 eyes were subjected to irrigation of the lens capsular bag with TTX-100 and DWI for 5 minutes without using SCI. The solution was delivered via a preloaded 20-mL syringe with a 27-gauge cannula inserted into the main wound. During this procedure, the anterior chamber was noted to inflate with pharmacologic irrigating solution, and at the end of treatment it was flushed with balanced salt solution. Group 3 eyes underwent selective irrigation of the capsular bag with TTX-100 and DWI for 5 minutes using SCI with PerfectCapsule.

The application of SCI has been previously described²⁷ and is briefly summarized here: a 3-mm corneal tunnel construction of up to 1.5 mm long was created, angulated slightly toward the center of the globe. Following irrigation and aspiration, the anterior chamber was filled with Provisc. PerfectCapsule was folded and inserted through a nonenlarged wound into the anterior chamber, then unfolded onto the anterior capsule and centered over the capsulorrhexis. Vacuum was applied and the device adhered to the anterior capsule. Sealing was confirmed with translational and rotational motion to visually confirm movement of the capsulorrhexis with the device. Once sealing was confirmed, the intact lens capsule was selectively irrigated with TTX-100 and DWI for 5 minutes. No sutures were placed, and no intraocular lens was implanted.

HISTOLOGICAL EVALUATION OF THE ENUCLEATED GLOBES

Immediately after the surgery, all of the rabbits were humanely euthanized. The eyes were enucleated and were immediately placed into 10% neutral buffered formalin. The globes were then dehydrated in alcohol and embedded in paraffin. After they were sectioned, they were stained with hematoxylin-eosin and periodic acid-Schiff. Three microsections were selected from the center of the lens capsule of each eye. Using a light microscope (Olympus; Optical Co Ltd, Tokyo, Japan), viable corneal endothelial cells and LECs were counted in the histological sections by the 2 observers (A.J.M. and S.K.P.) at a standard magnification of $\times 40$ in all 3 groups. A viable corneal endothelial cell or LEC is defined as a structure adherent to the Descemet membrane or lens capsule with an identifiable membrane (cell wall). Photomicrographs were taken for documentation.

For the purpose of histological evaluation, we define a viable cell as a normally appearing cell nucleus surrounded by cytoplasm and intact cell walls. In some cases, these cells may be artificially separated from the basement membrane owing to postmortem change and histological preparation. These cells were still considered viable. An example of a nonviable cell is a nucleus lying bare against a basement membrane, devoid of cell membrane and cytoplasm.

RESULTS

The surgical steps were uneventful in all of the eyes. Intraoperatively, the capsular bag was sealed and inflated in all treatment eyes in group 3. Irrigation could be performed for 5 minutes using SCI.

Table. Quantitative Details of Corneal Endothelial Cell and Lens Epithelial Cell Counts Evaluated in All 3 Groups*

Rabbit Eye Study Group	Mean ± SD Corneal Endothelial Cell Count per Field	Mean ± SD Anterior Lens Epithelial Cell Count per Field	Mean ± SD Equatorial Lens Epithelial Cell Count per Field
Group 1: control eyes, without treatment	35 ± 2.4	35 ± 2.2	84 ± 3.1
Group 2: treatment with DWI and TTX-100; without SCI	0	18 ± 1.2	39 ± 3.1
Group 3: treatment with DWI and TTX-100; with SCI	27 ± 1.2	1 or 2	0

Abbreviations: DWI, demineralized water for injection; SCI, sealed capsule irrigation; TTX-100, Triton X-100.

*Presence of viable corneal endothelial/lens epithelial cells was counted in the histological sections at the standard ×40 magnification in all 3 groups. The viable cell is defined as a structure adherent to the Descemet membrane/lens capsule with an identifiable membrane (cell wall).

HISTOLOGICAL EVALUATION OF THE ENUCLEATED GLOBES

In group 1 (control), assessment of the cornea, anterior segment, lens, and retina revealed normal histological findings in all of the eyes. In brief, the cornea showed a confluent healthy layer of endothelium; the lens capsular bag showed a confluent layer of LECs confined to the equator. Mean±SD anterior and equatorial LEC counts per field were 35±2.2 and 84±3.1, respectively (**Table**). The peripheral retina and uvea were normal (**Figure 2**).

In group 2 treatment eyes without SCI, all sections showed diffuse loss of corneal endothelial cells, with nuclear remnants scattered on the Descemet membrane. The iris showed loss of posterior epithelium and was thickened and swollen with vascular dilatation. The lens capsular bag appeared normal and was lined with both damaged and normal-appearing LECs (**Figure 3**). Mean±SD anterior and equatorial LEC counts per field were 18±1.2 and 39±3.1, respectively (**Table**). The peripheral retina showed significant cellular damage with loss of retinal ganglion cells and cleft formation (**Figure 3**). Damage extended beyond the anterior segment into the peripheral and posterior retina, with diffuse cell lysis.

In group 3 treatment eyes with SCI, the cornea had a normal histological appearance with a confluent layer of endothelium; the lens capsular bag showed absence of LECs or nuclear debris scattered along its entire length internally. Mean anterior and equatorial LEC counts per field were 1 or 2 and 0, respectively (**Table**). The iris showed a double pigmented layer of normal thickness, and the peripheral retina had a normal histological appearance (**Figure 4**).

COMMENT

Opacification of the posterior capsule caused by postoperative proliferation of cells in the capsular bag remains the most frequent complication of cataract-intraocular

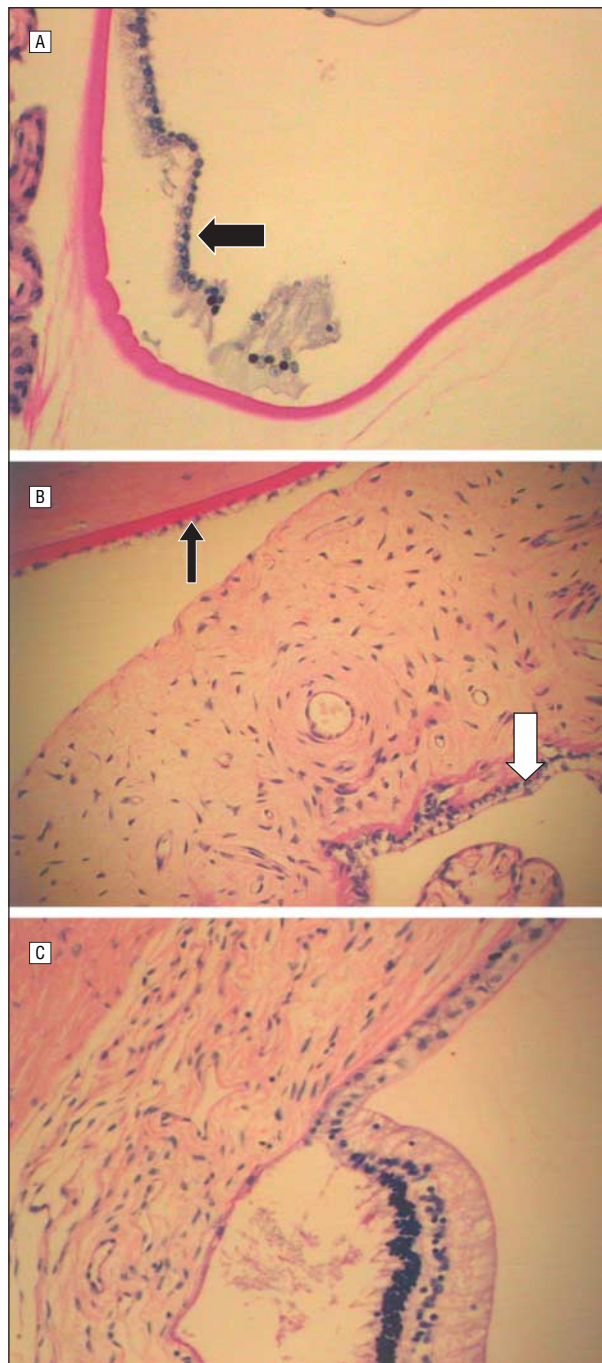


Figure 2. Histological findings of the rabbit eyes in group 1 (phacoaspiration surgery without any treatment, control group). A, The capsular bag. Note the presence of residual viable lens epithelial cells (arrow) within the capsular bag (periodic acid–Schiff, original magnification ×40). B, Healthy corneal endothelial cells (black arrow) and posterior iris epithelium (white arrow) (periodic acid–Schiff, original magnification ×40). C, Undamaged retinal tissue and retinal pigment epithelium. There is postmortem artifactual detachment at the ora serrata (periodic acid–Schiff, original magnification ×40).

lens surgery.^{1,2} In addition to classic PCO, postoperative LEC proliferation is also involved in the pathogenesis of anterior capsule opacification or fibrosis and interlenticular opacification.^{1,2} Intraocular application of pharmacologic agents as a means to prevent postoperative proliferation of LECs has been investigated. Some of these agents include cancer chemotherapeutic drugs

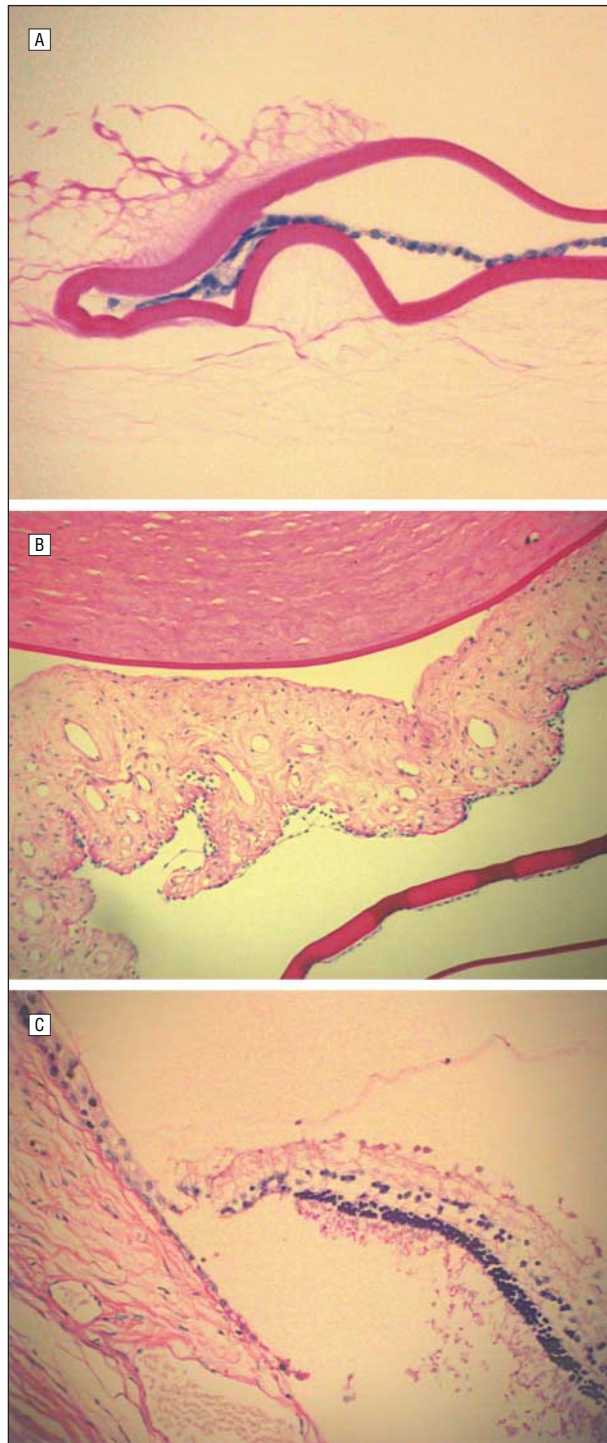


Figure 3. Histological findings of the rabbit eyes in group 2 (phacoaspiration surgery and nonselective irrigation of the capsular bag with demineralized water for injection and Triton X-100 without sealed capsule irrigation). A, The collapsed fornices of the capsular bag. Note the presence of viable lens epithelial cells at the anterior and equatorial region of the capsular bag (periodic acid–Schiff, original magnification $\times 40$). B, Almost total loss of corneal endothelial cells, with bare Descemet membrane. There is a loss of integrity of posterior iris epithelium (periodic acid–Schiff, original magnification $\times 40$). C, The peripheral retina showing significant disorganization of the retinal tissue and retinal pigment epithelium (periodic acid–Schiff, original magnification $\times 40$).

(eg, antimetabolites such as methotrexate, mitomycin, daunomycin, 5-fluorouracil, colchicine, and daunorubicin), anti-inflammatory substances, hypo-osmolar drugs,

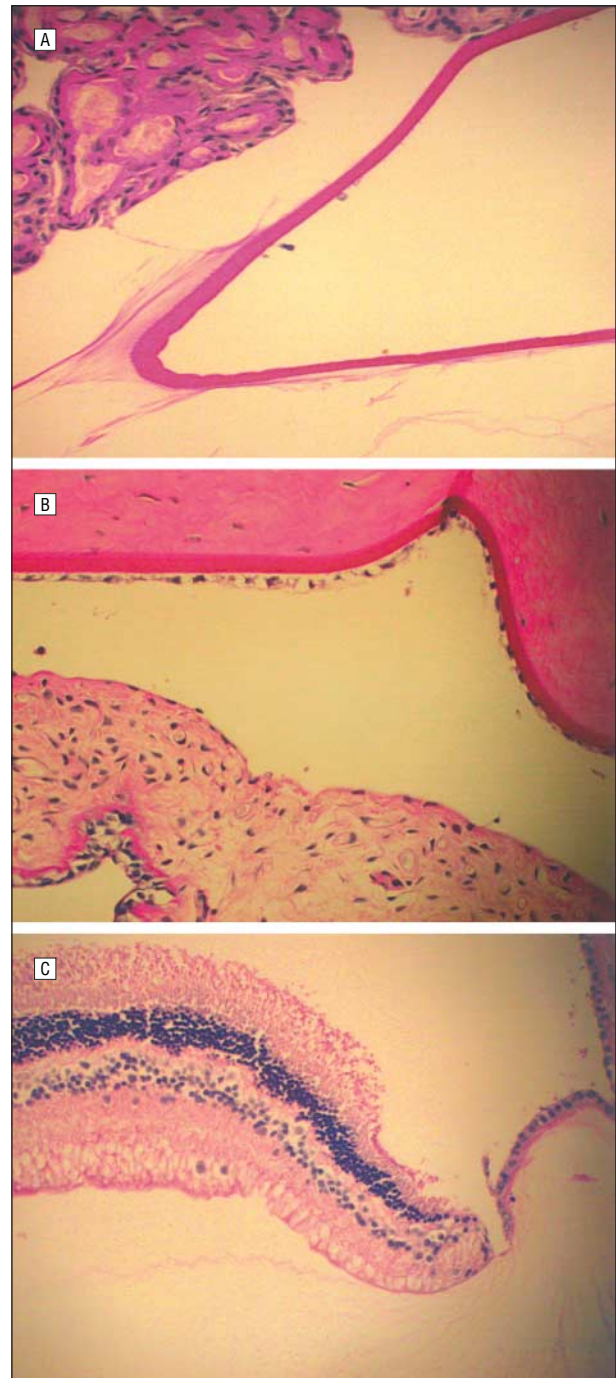


Figure 4. Histological findings of the rabbit eyes in group 3 (phacoaspiration surgery and selective irrigation of the capsular bag with demineralized water for injection and Triton X-100 with sealed capsule irrigation). A, The capsular bag. Note the absence of viable lens epithelial cells within the capsular fornices. Some nuclear remnants are visible lying on the capsule (periodic acid–Schiff, original magnification $\times 40$). B, Healthy corneal endothelial cells and posterior iris epithelium (periodic acid–Schiff, original magnification $\times 40$). C, Undamaged peripheral retinal tissue and retinal pigment epithelium (periodic acid–Schiff, original magnification $\times 40$).

and immunoconjugate (MDX-RA; Medarex Inc, Princeton, NJ) and immunological agents.¹⁴⁻²⁵ Immune targeting has been investigated using ricin A immunotoxin²⁶ with good effect, but it is complicated by suspected collateral damage to the retina, possibly due to a cross-reaction of the antibody with retinal epithelium.

The specific delivery of agents to LECs has been difficult. Therefore, toxic side effects to corneal endothelium and other ocular structures remains a major concern for using cancer chemotherapeutic drugs, anti-inflammatory substances, hypo-osmolar drugs, and immunological agents when the intralenticular compartment is in direct contact with the anterior chamber. However, with the development of PerfectCapsule based on the principle of SCI, it is now possible to precisely deliver the pharmacologic/hypo-osmolar agents to the LECs within the capsular bag while minimizing the potential for collateral ocular damage.^{27,28}

This current pilot study was designed to assess the immediate effect of a toxin (TTX-100) in rabbit eyes. Rabbits are a well-investigated, accelerated model for LEC activity after cataract surgery owing to the aggressive nature of the LEC proliferation that occurs. Although structurally similar to human eyes, there are notable differences between rabbit and human eyes that influence investigation. The rabbits were euthanized and the eyes were fixed immediately after surgery to assess the toxic effect and to eliminate any possible regenerative potential of rabbit corneal endothelial cells.

Although not suitable for human use, TTX-100 was chosen in this experimental study owing to its powerful nonselective toxic effect on cells.²⁹ Very small amounts of TTX-100 are required to elicit irreparable cell damage. In an *in vitro* study using fresh human LECs obtained from anterior capsulotomy specimens, it was our experience that TTX-100 leads to complete destruction of LECs within 1 minute of contact. In the rabbit model, irrigation of the anterior chamber leads to toxic reactions seen as far as the peripheral retina, which shows dramatic evidence of damage in all of the eyes of group 2. The likely pathway is a direct passage of toxin around the anterior capsule and the hyaloid face and into the retinal periphery. A significant finding is that irrigation of the anterior segment without SCI has a limited effect on LECs in the rabbit model, and this is possibly owing to incomplete contact between the irrigating fluid and the LECs, which occurs with a collapsed capsular bag. Positive pressure inflation of the capsular bag is a necessary requirement for destruction of the LECs in this model.

By contrast, irrigation of the lens capsular bag of the rabbit under sealed conditions using the principle of SCI allows positive pressure inflation of the capsular fornices, ensuring complete contact of the LECs with the toxic agent. Nuclear remnants were seen adherent to the anterior capsule, and no viable LECs were seen in the histological sections in the capsular fornices (Table). There was no evidence of collateral damage in the rest of the ocular structures after 5 minutes of continuous positive pressure irrigation of the lens capsular bag with TTX-100 and DWI using PerfectCapsule. As a future development, descriptions of chemical methods of lens removal exist and are based on a pharmacologic method for dissolution of the crystalline lens. It is a distinct possibility that SCI may facilitate the pharmacologic means for crystalline lens removal.

The current experimental study clearly indicates the safer delivery of highly toxic detergent (TTX-100) in the rabbit capsular bag using SCI. Histological

evaluation confirmed selective damage to the LECs in group 3, without ultrastructural damage to adjacent ocular structures such as corneal endothelium, iris, ciliary body, and retina (Figure 4, Table). The SCI allowed for positive pressure inflation of the capsular fornices, facilitating destruction of the residual LECs in these difficult to reach areas. Interestingly, the capsular fornices were clear with scant LECs seen on the anterior capsule. Uncontrolled delivery of TTX-100 was unable to damage the LECs in group 2 since the capsular fornices likely remained uninflated and the toxin could not interact with residual LECs. Further, an attempt to irrigate the "open" (nonsealed) capsular bag resulted in TTX-100 spillover to other ocular tissues, which is consistent with the histological findings that suggest loss of corneal endothelium and cellular damage to iris and retinal tissues in group 2 eyes (Figure 3, Table). Quantitative LEC analysis indicated that positive pressure inflation of the capsular bag is required to treat the equatorial LECs.

The potential damage from permeation of TTX-100 through the rabbit lens capsular bag after a brief irrigation of 5 minutes using SCI was not evident in the histological evaluation. However, analyses of the anterior chamber aqueous sample using appropriate techniques to detect the presence of any residual amount of TTX-100 may be done in future studies.

In summary, positive pressure inflation of the capsular bag is a necessary requirement for exposure of the LECs in the rabbit model. The SCI allows for isolation of LECs and positive pressure inflation of the capsular bag. Using PerfectCapsule, it is possible to induce selective death of LECs in the rabbit using TTX-100 with histological evidence of no collateral damage to other ocular structures. The definitive agent to be used with SCI remains unknown, and it is unlikely to require such high toxicity. The ultimate aim may be to induce apoptosis, or deactivation, in the LECs rather than to induce immediate cell death. Long-term studies and multicentric clinical trials may be helpful in testing the efficacy of SCI to prevent the postoperative cellular proliferation of LECs in the capsular bag. Sealed capsule irrigation is currently under evaluation in human eyes using continuous DWI irrigation of the lens capsular bag immediately following lens removal to assess its efficacy in elimination of the capsular opacification and in preventing proliferation of LECs.

Submitted for Publication: June 11, 2004; accepted February 7, 2005.

Correspondence: Anthony J. Maloof, MBBS, MBIomedE, FRANZCO, FRACS, 1 Western Sydney Eye Hospital, Hawkesbury Rd, Westmead Hospital, Westmead NSW 2145, Australia (drmalooof@cornea-eyeplastics.com.au).

Financial Disclosure: Dr Maloof is the inventor of the PerfectCapsule device. Dr Milverton and Mr Nielson hold positions in Milvella Pty Ltd, which markets the PerfectCapsule device.

Previous Presentation: Presented in part as Best Paper of Session at the Annual Meeting of the American Society of Cataract & Refractive Surgeons; May 4, 2004; San Diego, Calif.

Acknowledgment: Roger Crouch, MBBS, South Eastern Area Laboratory Service, The Prince of Wales Hospital, Randwick, Australia, provided assistance with histopathological evaluation.

REFERENCES

1. Apple DJ, Peng Q, Visessoon N, et al. Eradication of posterior capsule opacification: documentation of a marked decrease in Nd:YAG laser posterior capsulotomy rates noted in an analysis of 5416 pseudophakic human eyes obtained postmortem. *Ophthalmology*. 2001;108:505-518.
2. Apple DJ. Influence of intraocular lens material and design on postoperative intracapsular cellular reactivity. *Trans Am Ophthalmol Soc*. 2000;98:257-283.
3. Apple DJ, Solomon DK, Tetz MR, et al. Posterior capsule opacification. *Surv Ophthalmol*. 1992;37:73-116.
4. Nishi O. Posterior capsule opacification, part 1: experimental investigations. *J Cataract Refract Surg*. 1999;25:106-117.
5. Schaumberg DA, Dana MA, Christen WG, Glynn RJ. A systematic overview of the incidence of posterior capsule opacification. *Ophthalmology*. 1998;105:1213-1221.
6. Werner L, Apple DJ, Pandey SK. Postoperative proliferation of anterior and equatorial lens epithelial cells: a comparison between various foldable IOL designs. In: Buratto L, Osher R, Masket S, eds. *Cataract Surgery in Complicated Cases*. Thorofare, NJ: Slack; 2000:399-417.
7. Ram J, Pandey SK, Apple DJ, et al. The effect of in-the-bag fixation on the prevention of posterior capsule opacification. *J Cataract Refract Surg*. 2001;27:1039-1046.
8. Pandey SK, Apple DJ, Werner L, et al. Posterior capsule opacification: a review on aetiopathogenesis, experimental and clinical studies and factors for prevention. *Indian J Ophthalmol*. 2004;52:99-112.
9. Pandey SK, Wilson ME, Trivedi RH, et al. Pediatric cataract surgery and intraocular lens implantation: current techniques, complications and management. *Int Ophthalmol Clin*. 2001;41:175-196.
10. Apple DJ, Peng Q, Visessoon N, et al. Surgical prevention of posterior capsule opacification, part I: progress in eliminating this complication of cataract surgery. *J Cataract Refract Surg*. 2000;26:180-187.
11. Peng Q, Apple DJ, Visessoon N, et al. Surgical prevention of posterior capsule opacification, part 2: enhancement of cortical clean up by focusing on hydrodissection. *J Cataract Refract Surg*. 2000;26:188-197.
12. Peng Q, Visessoon N, Apple DJ, et al. Surgical prevention of posterior capsule opacification, part 3: intraocular lens optic barrier effect as a second line of defense. *J Cataract Refract Surg*. 2000;26:198-213.
13. Werner L, Pandey SK, Escobar-Gomez M, et al. Anterior capsule opacification: a histopathological study comparing different IOL styles. *Ophthalmology*. 2000;107:463-471.
14. Nagamoto T, Eguchi G. Effect of intraocular lens design on migration of lens epithelial cells onto the posterior capsule. *J Cataract Refract Surg*. 1997;23:866-872.
15. Ruiz JM, Medrano M, Alio JL. Inhibition of posterior capsule opacification by 5-fluorouracil in rabbits. *Ophthalmic Res*. 1990;22:201-208.
16. Tetz MR, Ries MW, Lucas C, et al. Inhibition of posterior capsule opacification by an intraocular-lens-bound sustained drug delivery system: an experimental animal study and literature review. *J Cataract Refract Surg*. 1996;22:1070-1078.
17. Ismail MM, Alio JL, Moreno JMR. Prevention of secondary cataract by antimetabolic drugs: experimental study. *Ophthalmic Res*. 1996;28:64-69.
18. Legler UFC, Apple DJ, Assia EI, et al. Inhibition of posterior capsule opacification: the effect of colchicine in a sustained drug delivery system. *J Cataract Refract Surg*. 1993;19:462-470.
19. Nishi O, Nishi K, Mano C, et al. Inhibition of migrating lens epithelial cells by blocking the adhesion molecule integrin: a preliminary report. *J Cataract Refract Surg*. 1997;23:860-865.
20. Power WJ, Neylan D, Collum LMT. Daunorubicin as an inhibitor of human lens epithelial cell proliferation in culture. *J Cataract Refract Surg*. 1994;20:287-290.
21. Nishi O, Nishi K, Morita T, et al. Effect of intraocular sustained release of indomethacin on postoperative inflammation and posterior capsular opacification. *J Cataract Refract Surg*. 1996;22:806-810.
22. Inan UU, Ozturk F, Kaynak S, et al. Prevention of posterior capsule opacification by intraoperative single-dose pharmacologic agents. *J Cataract Refract Surg*. 2001;27:1079-1087.
23. Pandey SK, Cochener B, Apple DJ, et al. Intracapsular ring sustained 5-fluorouracil delivery system for prevention of posterior capsule opacification in rabbits: a histological study. *J Cataract Refract Surg*. 2002;28:139-148.
24. Fernandez V, Frago MA, Billotte C, et al. Efficacy of various drugs in the prevention of posterior capsule opacification: experimental study of rabbit eyes. *J Cataract Refract Surg*. 2004;30:2598-2605.
25. Meacock WR, Spalton DJ, Hollick EJ, et al. Double-masked prospective ocular safety study of a lens epithelial cell antibody to prevent posterior capsule opacification. *J Cataract Refract Surg*. 2000;26:716-721.
26. Tarsio JF, Kelleher PJ, Tarsio M, Emery JM, Lam DM. Inhibition of cell proliferation on lens capsules by 4197X-ricin A immunoconjugate. *J Cataract Refract Surg*. 1997;23:260-266.
27. Maloof A, Neilson G, Milverton EJ, Pandey SK. Selective and specific targeting of lens epithelial cells during cataract surgery using sealed-capsule irrigation. *J Cataract Refract Surg*. 2003;29:1566-1568.
28. Crowston JG, Maloof A, Healey PR, et al. Water modulation of lens epithelial cells during cataract surgery. *J Cataract Refract Surg*. 2003;29:2464-2465.
29. Parnigotto PP, Bassani V, Montesi F, Conconi MT. Bovine corneal stroma and epithelium reconstructed in vitro: characterisation and response to surfactants. *Eye*. 1998;12:304-310.