



OCULAR SURGERY NEWS EUROPE/ASIA-PACIFIC EDITION May 2004

## Sealed capsule device helps prevent PCO

**The device seals the rhexis and allows irrigation of the capsular bag.**

*Amar Agarwal, FRCS, FRCOphth; Anthony J. Maloof, MBBS, MBIomedE, FRANZCO, FRACS; Sunita Agarwal, MS, FSVH, DO; Athiya Agarwal, MD, DO*


Posterior capsular opacification is a persistent problem in cataract surgery. It has not been possible to effectively isolate and specifically target lens epithelial cells following phacoemulsification.

One of the authors (AJM) developed a disposable device called Perfect Capsule (Milvella Pty. Ltd.), which helps selective targeting of the lens epithelial cells with a new technique called sealed capsule irrigation (SCI).

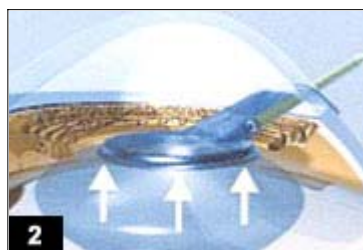
This device has been used in human eyes by many surgeons since its development. In July 2003 live surgery showing the device after phakonit cataract surgery under no anesthesia was telecast at the Indian Intraocular Implant and Refractive Surgery conference in Chennai, India, by one of us (Am A).

### Principle


Using an injection-molded silicone device (Figure 1), SCI isolates the internal lens capsule, including residual lens epithelial cells, from the rest of the eye. The basic idea is to seal the rhexis (Figure 2) and then irrigate the capsular bag with an irrigating solution (Figure 3), which would prevent PCO. The sealing of the capsule should be perfect, so the surgeon can irrigate the capsular bag without the solution leaking into the anterior chamber. Finally the device is removed from the eye (Figure 4).




**1**  
The Perfect Capsule is folded and inserted through a 3-mm incision.



**2**  
The Perfect Capsule is placed onto the capsular bag and vacuum-activated by a syringe.



**3**  
The capsular bag is irrigated.



**4**  
The device is removed from the eye.

All figures courtesy Amar Agarwal, FRCS, FRCOphth.

### Perfect Capsule

The Perfect Capsule SCI device is made of medical-grade silicone. It has an overall diameter of 7 mm and an inner diameter of 5 mm, and it was designed to temporarily seal a capsulorrhexis of less than 5 mm. The device uses a

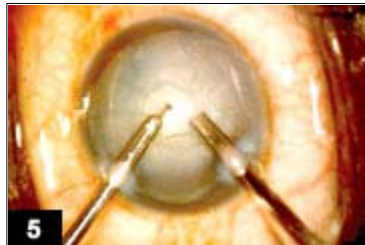vacuum ring (similar to that used to fixate the globe during LASIK) that attaches onto the outer surface of the anterior lens capsule and seals around the rhexis. There is a channel through which an irrigating solution can be passed into the capsular bag, and through that same area a channel for the outflow of the fluid.

### Surgical technique

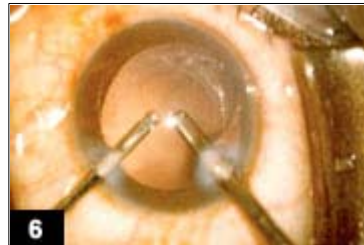The construction of the tunnel incision is important; it should be short and steep, pointing toward the rhexis. This allows proper placement of the Perfect Capsule on the capsular bag, especially in highly myopic eyes in which the anterior chamber is deep.

The next step is to perform a rhexis of less than 5 mm (Figure 5). After removal of the nucleus and aspiration of the cortical material (Figure 6), the chamber is filled with a small amount of viscoelastic.

Then the Perfect Capsule is removed from its sterile package. The device is held with forceps (Figure 7). Because it is soft it can be folded (Figure 8) and passed through a 3.2-mm incision (Figure 9). If phakonit has been performed, the 1-mm incision has to be enlarged.



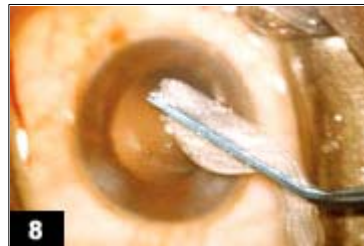**5**  
**Phakonit** is started after creation of a capsulorrhexis of less than 5 mm.



**6**  
**Bimanual irrigation** and aspiration is performed.



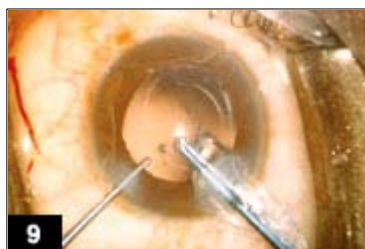**7**  
**The Perfect Capsule** device is held with forceps.



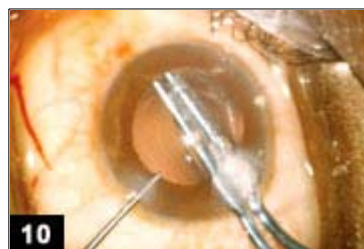
**8**  
**The device is folded** and held with forceps.

Once the device is folded, the forceps are passed into the anterior chamber with the Perfect Capsule (Figure 10), which unfolds inside the anterior chamber. Using the left hand with a globe stabilization rod, press gently on the device so that it touches the anterior capsule (Figure 11).

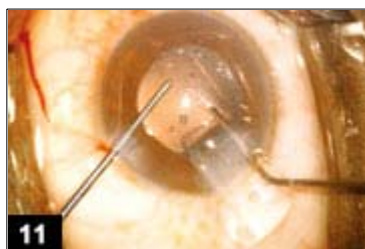Then the assistant is told to pull the syringe connected to the Perfect Capsule and lock it. This syringe creates a vacuum, so the device seals the rhexis margin (Figure 12). Be careful that the iris does not get stuck between the capsule and the Perfect Capsule.



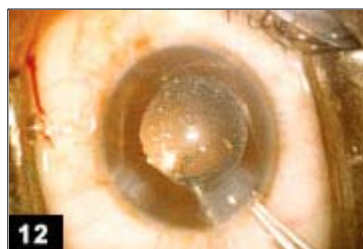**9**  
**The device is passed into the eye** using forceps..



**10**  
**The device is positioned** over the capsulorrhexis.



**11**  
Vacuum locks the device over the capsulorrhexis.



**12**  
Once the device is in place, irrigation of the capsular bag is performed with distilled water, and then the Perfect Capsule is removed.

Once the sealing has been done, trypan blue can be injected via a cannula through the opening in the Perfect Capsule meant for irrigation. The trypan blue will not leak into the anterior chamber, indicating the sealing is perfect. Then the capsular bag is irrigated with distilled water, which will not come into contact with any other structures as it passes in and out of the capsular bag. We used the air pump in the irrigation to improve the flow through the cannula.

The next step is to remove the Perfect Capsule. For this the assistant disengages the lock in the syringe to break the suction. Viscoelastic is gradually injected inside the eye, then the Perfect Capsule is disengaged from the capsule with the globe stabilization rod. Once it is free in the anterior chamber, the Perfect Capsule is pulled out of the eye. Because it is soft, it is easily removed without discomfort under topical anesthesia.

## Research

Further research is needed on the use of cytotoxic drugs that will prevent PCO. This is just the beginning, not the end. Today we are able to seal the capsular bag effectively, which can lead to many more uses in the future. We are now trying to modify the Perfect Capsule so it can be passed through a sub-1.5-mm incision to allow its use after phakonit. Then the microlenses will not need a sharp optic to reduce PCO.

The SCI device was developed with a focus on preventing PCO, but with all the feedback from surgeons who have seen and used it, SCI will find other uses. SCI is targeted to maintain a clear capsular bag and through this provide long-term quality of vision. This is immediately relevant in several areas:

- Any lens-based refractive procedure (accommodating lenses, clear lens extraction, multifocal lenses, piggyback lenses);
- Cataract surgery where in the future one can implant IOLs without sharp edges — and using lens materials that today are seen as inferior (eg, hydrophilic, silicone, etc.) — and so introduce optically improved materials with improved techniques like phakonit;
- Midterm relevance for retinal surgeons who benefit from clear capsules when doing a vitrectomy.

### For Your Information:

- Amar Agarwal, MS, FRCS, FRCOphth, can be reached at Dr. Agarwal's Eye Hospital & Eye Research Centre, 19 Cathedral Road, Chennai-600 086, Tamil Nadu, India; +91-44-2811-6233; fax: +91-44-2811-5871; e-mail: [dragarwal@vsnl.com](mailto:dragarwal@vsnl.com). Dr. Agarwal has no direct financial interest in the products mentioned in this article, nor is he a paid consultant for any companies mentioned.
- Anthony J. Maloof, MBBS, MBiomedE, FRANZCO, FRACS, can be reached at the Cornea and EyePlastics Institute, Level 4, 187 Macquarie St., Sydney 2000, Western Sydney Eye Hospital, Westmead 2145, New South Wales, Australia; +61-2-9247-9972; fax: +61-2-9345-0969; e-mail: [drmaloof@cornea-eyeplastics.com.au](mailto:drmaloof@cornea-eyeplastics.com.au). Dr. Maloof has a direct financial interest in the Perfect Capsule device mentioned in this article.

### References:

- Agarwal S, Agarwal A, et al. Phacoemulsification, Laser Cataract Surgery and Foldable IOLs. Second edition. Delhi, India: Jaypee Brothers; 2000.
- Boyd BF, Agarwal S, et al. LASIK and Beyond LASIK; Highlights of Ophthalmology. Panama: 2000.
- Agarwal et al. No anesthesia cataract surgery with karate chop. In: Agarwal's Phacoemulsification, Laser Cataract Surgery and Foldable IOLs. Second edition. Delhi, India: Jaypee Brothers; 2000: 217-226.